LA ROCHE-POSAY
LABORATOIRE DERMATOLOGIQUE

Cutaneous impact of oncology treatments: what we know in 2017

SKIN AND ONCOLOGY FOCUS

Systemic cancer therapy, radiotherapy, or a combination of the two have improved the management of many malignancies as well as patient survival rates. However, they are also associated with uncomfortable and disfiguring cutaneous reactions, which remain an important issue for both patients and treating physicians.[1]

Skin toxicity in oncology patients: an identified risk of poor compliance

Although mostly mild at onset, the cutaneous side effects of cancer treatments can become severe and significantly impair patients' quality of life.[1-3]
Their severity may even require dose reductions and interruptions, which can be detrimental to treatment outcome.[1,3]
And despite the benefits of antineoplastic therapies, their toxic effects on the skin may result in poor patient compliance and treatment discontinuation.[2]

In case of severe dermatological toxicities due to EGFR* inhibitors therapy	
36% **of healthcare providers modify dose**[4]	**72%** **of healthcare providers stop treatment**[4]

* Epidermal Growth Factor Receptor

To increase patients' wellbeing and improve adherence to treatment, it is critical for health teams treating oncology patients to recognize, prevent and treat these cutaneous adverse reactions.[3]

From radiotherapy to targeted therapies: a wide range of cutaneous adverse effects

On one hand, one of the most common side effects of radiation therapy is acute skin reaction occurring within the first six months.[5]
On the other hand, the cutaneous impact of chemotherapies (cytotoxic agents, targeted therapies) is comprehensively described.[1,2]

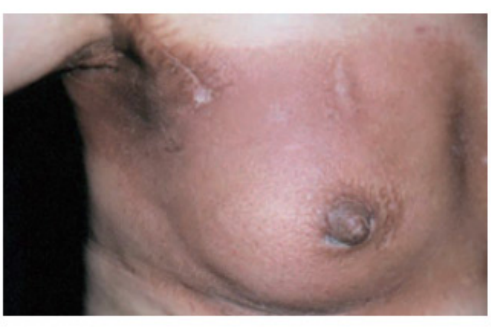
Early radiation dermatitis

Radiation

While the goal of radiotherapy is to provide maximum benefit to the patient with minimal side effects, up to 90% of patients will experience a dose-dependent skin reaction at the treated area, even with the most modern radiotherapy techniques.[6]
These skin reactions usually manifest within 1–4 weeks of starting radiation, persist throughout the therapy, and take 2–4 weeks to heal after its completion.[6]

Their severity is graded on a continuum ranging from mild erythema (red rash) and dry desquamation (itchy, peeling skin) to the more severe moist desquamation (open wound), and ultimately ulceration.[5,6]

GOING FURTHER

Skin toxicity with radiotherapy[6]

Tissue damage occurs immediately after the initial dose, and every subsequent fraction of radiation generates inflammatory cell recruitment.
Acute radiation dermatitis is the combined result of a decrease in functional stem cells, changes in the skin's endothelial cells, inflammation, and skin cell necrosis and death. Potential complications of radiation dermatitis in the acute setting include local infection.

The severity of the reaction is related to the dose per fraction, total dose delivered, use of bolus or other beam-modifying devices, size of the treatment field, site treated, use of concurrent chemotherapy or other agents, and individual susceptibility.

Body areas containing skin folds are at higher risk of developing a reaction because of a phenomenon called the "bolus effect"; these areas are more likely to receive a higher dose of radiation and more prone to bacterial contamination.

Systemic chemotherapy

It is well known that cytotoxic agents can cause side effects. [1,2]

CYTOTOXIC AGENTS' SIDE EFFECTS[1,2]

Hair and nails	Skin	Mucosa
• Alopecia • Paronychia • Melanonychia	• Skin rash or folliculitis • Skin dryness • Pruritus • Hand-foot syndrome • Hyperpigmentation	• Stevens–Johnson syndrome • Toxic epidermal necrolysis

Although targeted therapy has considerably increased survival rates in patients affected by large solid tumors in recent years, often this has been at the price of increased skin toxicity, as seen with EGFR inhibitors (i.e. skin dryness in more than 90% of patients, folliculitis that can be complicated by pruritus, pain and infection, etc.).[2]

GOING FURTHER

Chemotherapies and skin toxicity

Antimetabolites[2]
5-FU and capecitabine result in a distinctive sign of toxicity: hand-foot syndrome. Another sign of skin toxicity linked to the use of capecitabine is hyperpigmentation, also observed with cyclophosphamide and doxorubicin. Patients can present with black longitudinal pigmentation of the nails without any symptoms. These drugs are also associated with focal skin pigmentation, mainly involving the fingertips, combined with paresthesia or pain. According to some authors, these manifestations may be considered as initial signs of hand-foot syndrome.
The exact pathogenesis is unknown but may be related to the increased expression of the enzymes necessary for capecitabine activation in 5-FU in the skin on the fingertips. Damage to the nerve fibers seems to cause the neuropathic symptoms.

Spindle inhibitors[2] *(vinca alkaloids, taxanes): strictly related to alopecia and other skin diseases such as dermatitis, radiation recall, subacute cutaneous lupus erythematosus, nail abnormalities and ulcerations caused by extravasation, this reaction in particular is caused by direct damage to soft tissue.*

Genotoxic agents[2] *may cause severe, well-known, allergic IgE-mediated reactions, in particular platinum agents but also antibiotics. These can also lead to alopecia because they target proliferating cells, and particular effects like erythema flagellatum whose pathogenesis is unknown.*

EGFR inhibitors[2,3,5]
The common cutaneous reactions to EGFR inhibitors are labeled as PRIDE syndrome (Papulopustules and/ or paronychia, Regulatory abnormalities of hair growth, Itching and DrynEss).
EGFR fuels the growth of cancer cells. It also plays a role in the normal growth of the skin, hair, and nails. The EGFR receptor is expressed in the basal layer of the epidermis and promotes the differentiation of keratinocytes and follicular cells. Moreover, EGFR-inhibitors inhibit not only the EGFR when overexpressed in tumor cells, but also the receptor present on normal cells of the epidermis. The inhibition of EGFR in normal skin leads to alterations of growth and migration of keratinocytes that, together with inflammatory reactions, lead to xerosis and papulopustular skin rash, which is the most frequently reported toxic cutaneous effect.
Mucosa and cutis xerosis, varying from mild to more severe forms with eczema and fissures, has so far shown a variable incidence from 12% to 35% in clinical trials and often represents one of the cutaneous parameters persistently influencing patients' quality of life.
Nail alterations are frequently connected to the use of EGFR-inhibitors.

Cutaneous effects of systemic chemotherapy: the most common

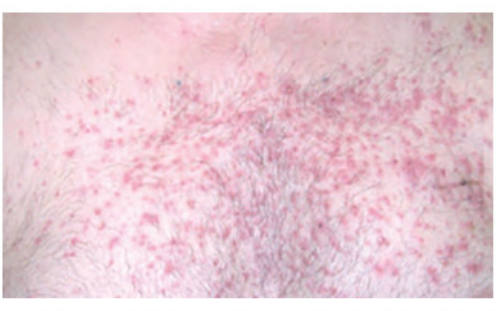
Follicular acneiform papulopustular eruption on the face and trunk associated with anti-EGFR therapy

Folliculitis (rash):

The most common reaction to systemic therapy, occurring in 43% to 85% of patients treated with targeted chemotherapy, and following a typical chronological pattern that peaks in severity during the first 1–2 weeks of treatment.[1,3]
This papulopustular follicular rash is defined as a form of acne since it primarily involves the face's seborrheic areas, scalp and chest and less frequently the extremities and back.
The eruption is accompanied by extremely irritating pruritus and can be complicated by bacterial over-infections, albeit short-lived. Its peculiar characteristic is the association of a typical sebaceous gland disease with marked xerosis, indicating that the main pathogenetic factor is not the cutaneous adnexa but the keratinocyte itself.[2]

Xerosis cutis:

The second most common side effect, appearing several weeks after treatment in up to 35% of patients receiving EGFR.[1,3] It is caused by abnormal keratinocyte differentiation, which induces an altered stratum corneum, a decrease in moisture retention and a reduction in epidermal loricrin, the main protein holding together the scaffolding of the epidermis.[3,4]

Xerosis can develop into xerotic dermatitis (asteatotic eczema), which can be complicated by secondary *Staphylococcus aureus* or Herpes simplex infection.[1,4]
Xerosis cutis and subsequent eczema are often correlated with older age and a tendency towards atopy. If dry skin appears on the hands or feet, patients may develop painful toes and fingertips (pulpitis sicca) or fissures on the dorsal sides of the interphalangeal joints.[1]


Xerosis

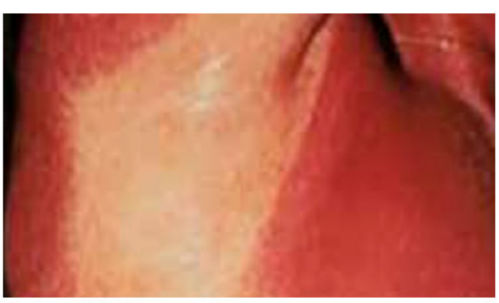
Photosensitization

Skin photosensitivity:

Skin toxicities such as rash and xerosis can be exacerbated by sun exposure. The skin becomes more sensitive to ultraviolet radiation, and in some cases sunlight can cause pigmentation changes.[1]

Paronychia:

A painful inflammatory reaction of the nail folds, which is difficult to treat and a possible cause of infection.[1]

Paronychia and periungual pyogenic-like lesions are frequent adverse reactions to EGFR inhibitors, appearing after one or two months of treatment in 10%–15% of patients due to the direct inhibition of keratinocytes in the nail matrix. The first lesions are usually localized on the big toe and the toes present with very painful erythema.[3]

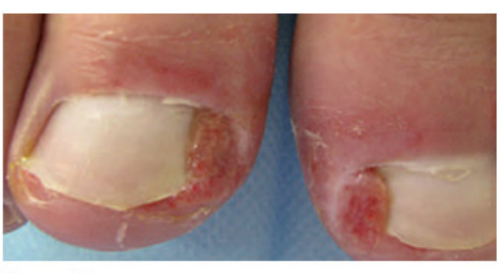
Paronychia

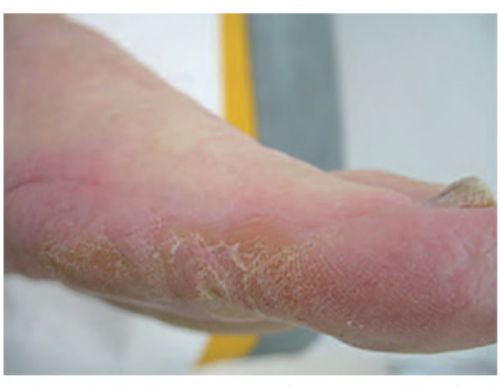
Hyperkeratotic erythrodysesthesia (hand-foot syndrome) associated with sorafenib therapy

Hand-foot syndrome:

The most severe side effect, particularly associated with capecitabine and other 5-fluorouracil derivatives.[1] Patients can present with erythema and swelling in mild cases, or blisters, ulceration and desquamation in severe cases. They also develop numbness and paranesthesia. Lesions are located on the palms of the hands and soles of the feet.[2]

To date, the pathophysiology of hand-foot syndrome has not been fully characterized. Involvement of the epidermis of the palms and soles, accompanied by damage to the epithelial cells of the eccrine ducts, suggests that this syndrome may entail more than a direct toxic effect on basal keratinocytes. Early recognition of hand-foot syndrome toxicity is important because it can progress quickly to higher grades of toxicity with debilitating consequences.[1]

Skin changes during oncologic treatment can be prevented: the American Cancer Association's recommendations[8]

Starting good skincare before you have side effects may help to minimize the problems. You may be asked to:

- Take baths instead of showers
- Bathe with cool or lukewarm (instead of hot) water
- Use very mild soaps, body washes, and shampoos that do not contain alcohol, perfume, or dye
- Moisturize the skin at least twice a day with a thick emollient cream that has no alcohol, perfumes, or dyes after you bathe, while your skin is still damp
- Wear loose, soft clothing
- Keep nails short
- Use laundry detergents or fabric softeners without strong perfumes
- Avoid hot, humid places
- Stay out of the sun as much as possible If you'll be outside during the day, wear a hat and clothes with long sleeves, use a broad-spectrum sunscreen with SPF of at least 30 and zinc oxide or titanium dioxide at least 1 hour before going out
- Try gel shoe inserts if the soles of your feet are tender
- Wear shoes that fit well and aren't too tight
- Do not use acne medicines. Though the rash may look like acne, acne medicines don't work. They can even dry it out and make it worse.
- Use makeup brands that can cover rashes without making them worse

GOING FURTHER

Cutaneous side effects of targeted therapies[2,3,7]

TYPE	SUBCLASS	MOLECULES	CUTANEOUS SIDE EFFECT
EGFR inhibitors	Monoclonal antibodies	Monoclonal antibodies Cetuximab, panitumumab	• Acnelike rash on face and upper body (cetuximab: 75%–91% of patients) • Increased sensitivity to sunlight • Inflammation around fingernails • Dry, itchy skin • Fingertip cracking • Hair loss on scalp • Increased, curly, or coarse hair on face and eyelashes
	Small-molecule tyrosine kinase inhibitors	Gefitinib, erlotinib, afatinib	• Acnelike rash on face and upper body (gefitinib: 24%–62% of patients – erlotinib: 49%–67%) • Increased sensitivity to sunlight • Inflammation around fingernails • Dry, itchy skin • Fingertip cracking • Hair loss on scalp • Increased, curly, or coarse hair on face and eyelashes
		Lapatinib	• Rash • Sores on lips, mouth, or throat • Dry skin • Red, painful, numb, or tingling hands and feet
		Vandetanib	• Skin redness • Rash or acne • Dry, peeling, or itchy skin • Blisters or sores
		Imatinib	• Dose-dependent maculopapular rash affecting the torso, forearms, and rarely the face
		Dasatinib	In 35% of patients, including: localized and generalized erythema, papular eruptions, exfoliative rash, pruritus, hyperhidrosis, alopecia, xerosis, acne, urticaria, dermatitis, photosensitivity, nail disorders and pigmentary changes, skin ulcers, palmoplantar erythrodysesthesia
		Ponatinib	Rash and dry skin in up to 40% of patients
		Nilotinib	Maculopapular rash in 28% of cases • Pruritus in 24% • Xerosis alopecia and bullous Sweet's syndrome in 12%
		Bosutinib	In 20%–44% of patients, including: erythema, maculopapular eruption, pruritic rash, allergic dermatitis, acne, folliculitis, skin exfoliation.
		Sorafenib, sunitinib	74% of patients receiving sorafenib and 81% of those taking sunitinib develop cutaneous adverse reactions, due to either the results of vessel damage by inhibition of PDGFR and VEGFR, or drug extravasation into the skin and mucosae • Hand-foot syndrome: the most common cutaneous adverse effect seen with sorafenib (62% of cases) and sunitinib (28%), especially at higher doses • Stomatitis 26% (sorafenib) – 36% (sunitinib) • Hair changes: alopecia in 26% (sorafenib) – 6% (sunitinib) • Redness and flaking on scalp and eyebrows • Warm, burning sensation on the face with redness • Dry, itchy skin
		Vemurafenib, dabrafenib	In 74% of patients, including: dose-dependent papulopustular rash (18% with vemurafenib, 27% with dabrafenib), photosensitivity (12% with vemurafenib), xerosis, pruritus, paronychia, alopecia and hair follicle alterations, hyperkeratosis
		Trametinib	• Acneiform rash (75% of cases) • Pruritus (27%) • Xerosis (22%)
Monoclonal antibodies targeting other molecules than EGFR		Bevacizumab, trastuzumab, obinutuzumab, pertuzumabinib	Non-specific erythematous rash
		Alemtuzumab	• Non-specific erythematous rash • Mouth sores
		Nivolumab	• ANon-specific erythematous rash • Hair loss • Yellowing of the skin and eyes • Itchy red rash
		Ofatumumab	• Non-specific erythematous rash • Hives • Sudden reddening of the face, neck, or chest • Pale skin
		Pembrolizumab	• Flushing, or skin redness • Change in skin color • Yellowing of skin and/or eyes • Hair loss
		Rituximab	• Non-specific erythematous rash • Redness, tenderness, swelling, or warmth of part of the skin
		Ipilimumab	• Bumpy red rash • Itching • Patches of pale skin and gray hair

Bibliography

1 - Bensadoun R-J., Humbert P., Krutman J., *et al*. Daily baseline skin care in the prevention, treatment, and supportive care of skin toxicity in oncology patients: recommendations from a multinational expert panel. Can Manag Res. 2013;5:401–8.
🔗 View the link to the free full text

2 - Fabbrocini G., Cameli N., Romano M.C., *et al*. Chemotherapy and skin reactions. J Exp Clin Cancer Res. 2012;31(1):50.
🔗 View the link to the free full text

3 - Lupu I., Voiculescu V.M., Bacalbasa N., *et al*. Cutaneous complications of molecular targeted therapy used in oncology. J Med Life 2016;9(1):19–25.
🔗 View the link to the free full text

4 - Lacouture M.E., Anadkat M.J., Bensadoun R-J., *et al*. Clinical practice guidelines for the prevention and treatment of EGFR inhibitor-associated dermatologic toxicities. Support Care Cancer 2011;19:1079–95.
🔗 View the link to the free full text

5 - Bolderston A., Lloyd N.S., Wong R.K.S. *et al*. The prevention and management of acute skin reactions related to radiation therapy: a systematic review and practice guideline. Support Care Cancer 2006;14(8):802–17.
🔗 View the link to the abstract

6 - Salvo N., Barnes E., van Draanen J. *et al*. Prophylaxis and management of acute radiation-induced skin reactions: a systematic review of the literature. Current Oncology 2010;17(4):94–112.
🔗 View the link to the free full text

7 - Skin Reactions to Targeted Therapy and Immunotherapy. Cancer.
🔗 View the link to visite the website

8 - Side Effects of Targeted Cancer Therapy Drugs.
🔗 View the link to visit the American Cancer Society website